

# Ethnicity Based Anatomical Variations in Malleus on Computerized Tomographic Scan

Mariya Azam Khattak<sup>1</sup>, Ambreen Usmani<sup>2</sup>, Ayesha Mehwish<sup>3</sup>, Rida Rubab Ahmad<sup>4</sup>,  
Maryam Faiz Qureshi<sup>5</sup> and Noman Ullah Wazir<sup>1</sup>

## ABSTRACT

**Objective:** To determine the anatomical variations in malleus among different ethnic groups

**Methodology:** An observational investigation was conducted within the Otorhinolaryngology and Radiology department of a public hospital in Karachi, (PNS) Shifa. In this study, 100 participants were included from January-July 2021 with ages ranging from 10-51 years. After obtaining consent and complete history from each participant, a detailed examination of ear was done. Subjects were arranged for petrous temporal bone (PTB) computed tomographic scans based on the inclusion criteria of no deformity concerning ear ossicles. The parameters considered for potential anatomical differences were width of malleus head, manubrium length, and complete malleus length.

**Results:** In 100 subjects, the mean  $\pm$ S.D (mm) for width of malleus head was  $3.02\pm 0.31$ , for manubrium length  $4.39\pm 0.46$  and complete malleus length was found to be  $7.59\pm 0.57$ . The value for length of manubrium among ethnic groups was found to be significant ( $p=0.05$ ).

**Conclusion:** Identification of these variations in such small bones is difficult but it is not impossible to comprehend, considering the availability of advance technologies. As, morphological variants can disrupt the prosthesis procedures, therefore, CT-PTB are suggested to acknowledge these modifications in size and shape. This study showed variations among groups.

**Key Words:** Ear ossicles, ethnicity, malleus, morphological variations, petrous temporal bone

**How to cite:** Khattak MA, Usmani A, Mehwish A, Ahmad RR, Qureshi MF, Wazir NU. Ethnicity based anatomical variations in malleus on computerized tomographic scan. *Ann Jinnah Sindh Med Uni.* 2024; 10(1):7-11  
DOI: 10.46663/ajsmu.v10i1.7-11

## INTRODUCTION

Hearing is an essential sense because it influences the mental, physical, and social well-being of an individual. It is one of the dominant senses and similar to vision, it is also used for cautioning and communication<sup>1</sup>. Like

a headset, the ear is animated by vibration. In the earpiece, the vibration changes into an electrical signal and then into an anxious motion in the ear in the form of sound which is then handled by the focal audible conduits of the mind, in which ear ossicles play a major role. This kind of mechanism is very complex<sup>2</sup>.

1 Department of Anatomy, Peshawar Medical College, Warsak Road, Peshawar. Pakistan

2 Professor and Principal, Department of Anatomy, Jinnah Medical and Dental College-Sohail University, Karachi, Pakistan

3 Department of Anatomy, Bahria University of Health Sciences, Karachi, Pakistan

4 Department of Anatomy, Shahida Islam Medical and Dental College, Multan Road, Lodhran, Pakistan

5 Department: Master of Science in Medical Sciences, Western University of Health Sciences, California, USA

**Correspondence:** Dr Mariya Azam Khattak, Assistant Professor (Anatomy), Peshawar Medical College, Warsak Road, Peshawar. Pakistan

**Email:** mariya\_rox@hotmail.com

**Received:** Oct. 24, 2023

**Revision:** Feb. 10, 2024

**Acceptance:** March 19, 2024

The ear comprises outer, middle, and inner sections. Within the air filled space of the middle ear, located in petrous temporal bone, the auditory ossicles can be appreciated, named malleus, incus, and stapes. They create a chain that delivers vibration of sound from middle to inner section cochlea, facilitating auditory reception<sup>3</sup>. Malleus bone sits in the middle ear between incus and tympanic membrane, which has two processes (anterior and lateral), a head, neck, and handle (manubrium). Incus also has two processes (short and long) and a body<sup>4</sup>. A synovial type of joint is present between the body of incus and malleus articulating surface and an 'incudostapedial joint' is present between stapes head and incus lenticular process<sup>5</sup>. The tiniest bones in human skeleton are the ossicles found in the middle section. Malleus being the largest amongst three, measures 8–9 mm in average length<sup>6</sup>.

Some scientists think that these ossicles reach a definite morphological form during the fetal period in human beings, and therefore, there are no noticeable variations, however, other studies contradict this idea<sup>7</sup>. These two different remarkable assertions motivated us to attempt to discover the variations found in the malleus of absolute adult size in different ethnic groups. One article reports that the ossification of malleus completes in intrauterine life (IUL)<sup>8</sup>. Another study also mentioned that how neonatal-ear dynamics changes with chronological age may be important in furthering hearing research and development of hearing devices and diagnostic tools suitable for neonates<sup>9</sup>. A study found that growth of ear ossicles in humans continues beyond the prenatal stage. The morphological parameters in the fetal periods vary noticeably in the post-natal life and that could be due to the bone remodeling phenomenon<sup>10</sup>.

These changes need to be added to anatomical information for future procedures for ear ossicles which must be planned carefully to avoid complications in prosthesis. Apart from cadaveric studies, no evident data was available which could help otorhinolaryngologists in appreciating these variations for making immediate decisions when planning any surgical procedure like prosthesis relating to this structure to maintain its functional reliability. Complete comprehension of the anatomy of a subject is crucial for gaining a deeper insight into how it functions and interacts within its context<sup>11</sup>.

Many studies mention anatomical variations in these structures but the information is insufficient to record these changes as these studies are mostly cadaveric. Due to the minute structure of these ossicles, they are extracted from cadavers and stored once in a while<sup>12</sup>. The varieties among people are fascinating organically, and are significant for procedures like ossiculoplasty and portable hearing assistants inserts after the birth<sup>13</sup>.

Many studies have been carried out worldwide on morphological variations of ear ossicles on cadavers but in Pakistan up to this point, no research paper in literature has explored this specific aspect and its significance in the field of surgery. Given the variations seen in different ethnic groups globally, it was crucial to undertake such a study in Pakistan. This formed an underlying rationale to conduct this study.

The objective of this study was to determine anatomical variations in malleus among different ethnic groups and see which morphological feature had significant variation in malleus bone.

## METHODOLOGY

An observational investigation was conducted within Otorhinolaryngology and Radiology department of a public hospital in Karachi (PNS) Shifa, between Jan and July 2021. Before starting this research, ethical approval was secured from the Ethical Review Committee of Bahria University of Health Sciences (ERC 62/2021). A software was used (open epi version 3 calculator) for sample size calculation indicating 100 participants. The study lasted for a total of six months, with each participant spending two hours for their individual study period. The quota sampling technique was used for 20 participants of each ethnicity. Participants from different ethnic groups, fulfilling the inclusion criteria with undamaged ear ossicles, were recruited. The participants had one ear with damaged ossicles (excluded from the study) and the other ear with undamaged ossicles, to fulfil the ethical criteria for avoiding unnecessary scans.

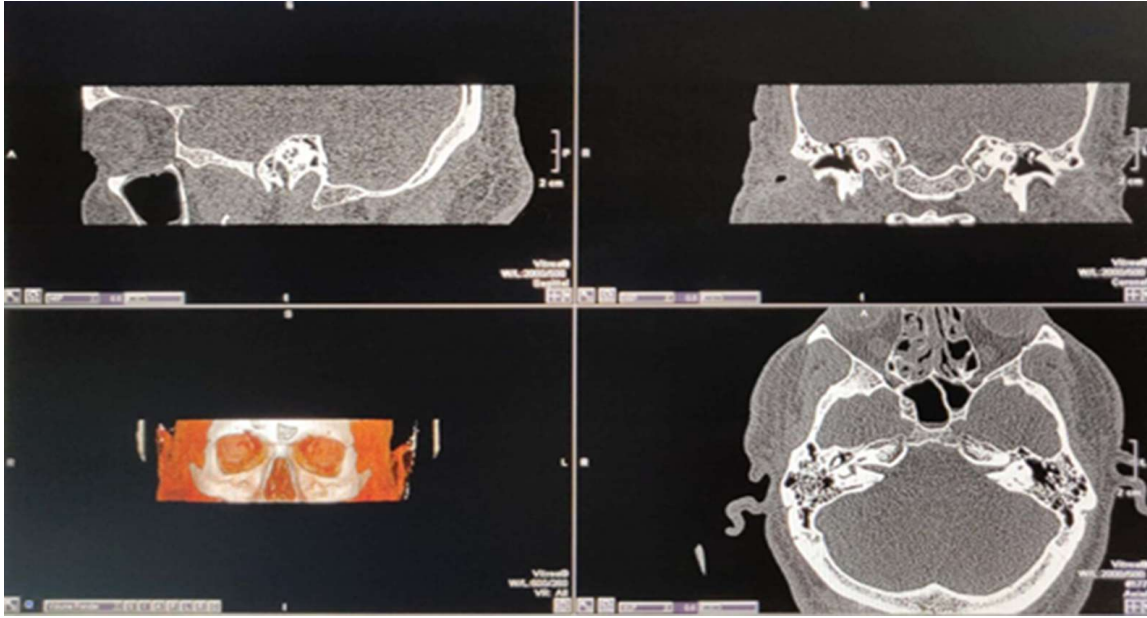
After obtaining written informed consent, participants from otorhinolaryngology were referred to the Radiology department. A Toshiba Prime CT scanner (Aquilion-160 slice) was used to perform a CT scan of petrous temporal bone. The individual was positioned fully supine and motionless on the 47 cm wide couch, following a comprehensive ear examination of each participant<sup>14</sup>. A software (Vitrea1.5.2265.3045) was used for measuring the anatomical variations in three distinct planes (coronal, sagittal, and axial). The malleus head width, manubrium length, and complete malleus length were the parameters taken into consideration. For accuracy, measurements were taken by making the landmarks. For malleus width, reference points were made on its upper part (Mup), a center point on its head (Mhead), and (Mneck) on its neck. For manubrium length, the points were marked from its neck (Mneck) till handle (Mhandle), and for complete length of malleus, a point on its upper point (Mup) and on its handle (Mhandle) were made<sup>15</sup>.

Data analysis was conducted using SPSS (version 23.0). Post Hoc Test was done with Anova for comparison of ethnic groups. Continuous data was written in mean  $\pm$  SD. The results with p-value = 0.05 were considered statistically significant.

## RESULTS

The study involved 100 participants who were evenly divided into subgroups of 20 each, irrespective of gender. The ethnic groups included Sindhi, Punjabi, Balochi, Pushto, and Urdu speaking people. The parameters included were malleus head width, its

**Malleus on HRCT in Three Planes**



**Table 1: Mean and Standard Deviation Observed in Ethnic Groups**

		N	Mean± SD (mm)	Confidence Interval 95% for Mean		Lowest	Highest
				Lower Limit	Upper Limit		
<b>Malleus (Width of Head)</b>	Sindhi	20	2.97±0.25	2.85	3.08	2.4	3.4
	Punjabi	20	3.03±0.37	2.86	3.21	2.3	3.4
	Balochi	20	3.03±0.31	2.89	3.17	2.5	3.5
	Pushto	20	3.17±0.28	3.04	3.30	2.7	3.6
	Urdu	20	2.89±0.27	2.76	3.01	2.5	3.3
	Total	100	3.02±0.31	2.96	3.08	2.3	3.6
<b>Length of Manubrium</b>	Sindhi	20	4.43±0.34	4.27	4.59	3.7	5.0
	Punjabi	20	4.12±0.31	3.98	4.27	3.5	4.6
	Balochi	20	4.52±0.59	4.24	4.80	3.5	5.5
	Pushto	20	4.43±0.35	4.27	4.59	3.9	5.1
	Urdu	20	4.45±0.58	4.18	4.72	3.8	5.6
	Total	100	4.39±0.46	4.30	4.48	3.5	5.6
<b>Total Length of Malleus</b>	Sindhi	20	7.55±0.40	7.36	7.73	6.7	7.9
	Punjabi	20	7.39±0.54	7.14	7.64	6.3	8.4
	Balochi	20	7.67±0.61	7.38	7.96	6.4	8.7
	Pushto	20	7.71±0.53	7.46	7.96	6.8	8.9
	Urdu	20	7.61±0.74	7.27	7.96	6.7	8.8
	Total	100	7.59±0.57	7.47	7.70	6.3	8.9

complete length and manubrium length. The mean and standard deviation of each parameter were noted for each ethnicity that showed the mean total length of malleus to be 7.59±0.57 mm, length of manubrium to be 4.39±0.46 mm, and width of malleus head was

noted to be 3.02±0.3 mm (Table: 1). These were then compared between sub-groups and a test was applied which showed that the length of manubrium had a significant value (p= 0.05) shown in (Table: 2).

**Table 2: Significant Morphological Reading in Malleus**

		Mean Square	F	p value
<b>Malleus (Width of Head)</b>	Between Groups	0.20	2.35	0.06
	Within Groups	0.09		
<b>Length of Manubrium</b>	Between Groups	0.48	2.37	0.05*
	Within Groups	0.20		
<b>Total Length of Malleus</b>	Between Groups	0.31	0.95	0.44
	Within Groups	0.33		

\*significant at 0.05

## DISCUSSION

Research from the literature indicates that the morphometric data acquired can have valuable applications in reconstructive procedures. It is recommended to perform preoperative radiological assessments for these small bones. It is equally important for both medical research and training to comprehend the typical and uncontrolled inconsistency of anatomical structures in humans (e.g. reconstruction of the middle ear ossicular chain, ossiculoplasty); and anthropological research focused on assessing variations at the population level, like examining diversity<sup>16</sup>. The gold standard for identification of middle ear diseases that cause ossicles erosion and morphological modifications are high-resolution CT scans that are fastest and easiest means of investigation to do so<sup>17</sup>.

A comparison of these discrepancies in different populations is a good prospective to know how these ossicles vary among different groups of people around the world. Any environmental factors are insignificant to cause any parametric changes in shape and size of these ossicles postnatally, whereas during skull development, they go through a medio-lateral shift<sup>18</sup>. An analysis was conducted on the morphological characteristics of the ear ossicles of both sides. It summarized that no significant variations were seen in the sides of the ear<sup>19</sup>.

A study also revealed that malleus shape had bilateral symmetry concluding negligible dimensional variations between both sides of the ear<sup>20</sup>. In accordance to this, the current study included ear ossicles irrespective of side of the ear. Studies done on different populations showed variability in malleus characteristics. A study on Central Europe, Poland population recovered human ear ossicles, analyzed malleus and documented that the mean total length was found to be significant as compared to this current study that showed variation in length of manubrium to be prominent<sup>21</sup>. In both sides, height range of malleus bone was measured. Statistically, the left malleus bone was longer and

heavier than its right counterpart showing the difference in malleus morphology between sides of the ear<sup>22</sup>. For prosthesis fitting, significant variation in all dimensions of each ossicle between individuals were noted to optimize prosthesis fit. From published data, an accurate 3-D model of these ossicles could be created, which can then be further modified for each patient's individual anatomy<sup>23</sup>.

Ossicles of ancestors were matched with modern humans, using different techniques, and concluded that size changes in brain with time, resulted in alterations in middle ear cavity, subsequently, modifying the shape and morphology of these bones. However, it had a negligible effect on hearing outcomes, resulting in variations in different ethnic groups as compared to the current study<sup>24</sup>. Mostly variations were observed in its distal portion (manubrium free end) and in lateral and anterior processes. Variations in morphology were observed mainly in free ends of manubrium which curved anteriorly in 29 (55.8%) while straight free ends of manubrium were observed in 23 (44.2%) malleus. Among some mallei, the lateral processes exhibited notable variation, with certain instances having elongated and sharp features, while others appeared blunter. Additionally, the length of the anterior process displayed variability, including one case where the process was extremely tiny and rounded, nearly absent<sup>25</sup>.

The current study showed variations in the length of manubrium, due to different shaped ends of manubrium (straight/curved). It was therefore similar to studies in literature that focused on different regions showing dimensional changes. In addition, the current study also showed variations among different ethnic groups in a country as mentioned in Table No. 1.

## CONCLUSION

In this study, variations in the morphology of ear ossicles with respect to their sizes were compared in different ethnic groups. The malleus manubrium exhibited the most frequent anatomical variation with significant value, which could be due to its shape (curved/straight manubrium) in different individuals related to bone remodeling phenomena with time. The mean width of malleus head and its complete length was found to be greater in Pushto ethnic group and for the length of manubrium, it was found to be greater in Balochi group as compared to other groups. A radiological technique was first time used to measure and assess these variations.

**Limitation of study:** Multicenter studies must be done in order to increase the scope of investigation. This research was a part of thesis; therefore, the study was single centered because of limited time.



**Conflict of interest:** Authors declare that there is no conflict of interest.

**Authors' Contributions:** MAK worked on methodology and prepared a manuscript draft; AU supervised the research; AM conceptualized and guided; RRA worked on data collection, review and editing; MFQ critically reviewed the final draft; NUW assisted in study and proof reading.

**Funding:** Nil

## REFERENCES

- Sundar PS, Chowdhury C, Kamarthi S. Evaluation of human ear anatomy and functionality by axiomatic design. *Biomimetics* (Basel). 2021; 6(2): 31. <https://doi.org/10.3390/biomimetics6020031>
- Priyadarshini RA, Arivazhagan S, Arun M. A deep learning approach for person identification using ear biometrics. *Applied Intel*. 2021; 51:2161-2172. DOI:10.1007/s10489-020-01995-8
- Lui CG, Kim W, Dewey JB, Macías-Escrivá FD, Ratnayake K, Oghalai JS, et.al. In vivo functional imaging of the human middle ear with a hand-held optical coherence tomography device. *Biomed Opt Express*. 2021;12(8):5196-5213. doi: 10.1364/BOE.430935.
- Snell RS. *Snell's Clinical Anatomy*. Wolters Kluwer India Pvt Ltd; 2018. 10<sup>th</sup> Edition.
- Mason MJ. Structure and function of the mammalian middle ear. II: Inferring function from structure. *J Anat*. 2016;228(2):300-12. doi: 10.1111/joa.12316
- Mansour S, Magnan J, Ahmad HH, Nicolas K, Louryan S. *Comprehensive and clinical anatomy of the middle ear cavity*. *J Otolaryngol-Head & Neck Surg*; 2019. 49-81. <https://doi.org/10.1007/978-3-030-15363-2>
- Anthwal N, Thompson H. The development of the mammalian outer and middle ear. *J Anat*. 2016; 228(2): 217-32. doi: 10.1111/joa.12344.
- Nuñez-Castruita A, López-Serna N. Morphometric study of the human malleus during prenatal development. *Int J Pediatr Otorhinolaryngol*. 2022;156:111113. <https://doi.org/10.1016/j.ijporl.2022.111113>
- Kanka N, Murakoshi M, Hamanishi S, Kakuta R, Matsutani S, Kobayashi T, et.al. Longitudinal changes in dynamic characteristics of neonatal external and middle ears. *Int J Pediatr Otorhinolaryngol*. 2020;134: 110061. doi: 10.1016/j.ijporl.2020.110061.
- Rolvien T, Schmidt FN, Milovanovic P, Jähn K, Riedel C, Butscheidt S, et.al. Early bone tissue aging in human auditory ossicles is accompanied by excessive hypermineralization, osteocyte death and micropetrosis. *Sci Rep*. 2018;8(1):1920. doi: 10.1038/s41598-018-19803-2.
- Dairaghi J, Rogozea D, Cadle R, Bustamante J, Moldovan L, Petrasche HI, et.al. 3D Printing of Human Ossicle Models for the Biofabrication of Personalized Middle Ear Prostheses. *Appl Sci*. 2022; 12(21): 11015. [doi.org/10.3390/app122111015](https://doi.org/10.3390/app122111015)
- Pipping B, Dobrev I, Schär M, Chatzimichalis M, Röösl C, Huber AM, et.al. Three-dimensional Quasi-Static Displacement of Human Middle-ear Ossicles under Static Pressure Loads: Measurement Using a Stereo Camera System. *Hear Res*. 2023;427:108651. doi:10.1016/j.heares.2022.108651
- Tsetsos N, Vlachtsis K, Stavrakas M, Fyrmpas G. Endoscopic versus microscopic ossiculoplasty in chronic otitis media: a systematic review of the literature. *Eur Arch Otorhinolaryngol*. 2021;278(4):917-923. doi: 10.1007/s00405-020-06182-6.
- Khale A, Baviskar S, Chandak T, Baviskar P, Bagle T, More M. Role of HRCT temporal bone in pre-operative evaluation in unsafe ear diseases. A hospital record based retrospective study in Thane, Maharashtra. *Glob J Med & Pub Health*. 2023;12(4):5.
- Li J, Chen K, Li C, Yin D, Zhang T, Dai P. Anatomical measurement of the ossicles in patients with congenital aural atresia and stenosis. *Int J Pediatr Otorhinolaryngol*. 2017;101:230-234. doi: 10.1016/j.ijporl.2017.08.013.
- Plack CJ. *The sense of hearing*. Routledge; 2018. 3<sup>rd</sup> Edition. <https://doi.org/10.4324/9781315208145>
- Pham N, Raslan O, Strong EB, Boone J, Dublin A, Chen S, et.al. High-Resolution CT Imaging of the Temporal Bone: A Cadaveric Specimen Study. *J Neurol Surg B Skull Base*. 2022;83(5):470-475. doi: 10.1055/s-0041-1741006.
- Cunningham C, Scheuer L, Black S. *Developmental juvenile osteology*. Academic press; 2017. 2<sup>nd</sup> Edition.
- Kumar BS, Anjum A, Vallinayagam R, Selvi GP, Vendhan KE. Morphometry of Human Ear Ossicles. *Arch Med Health Sci*. 2023; 11(2): 234-237. DOI:10.4103/amhs.amhs\_16\_23.
- Todd Jr NW, Daraei P. Morphologic variations of clinically normal mallei and incudes. *Ann Otol Rhinol Laryngol*. 2014;123(7):461-7. doi:10.1177/0003489414527228.
- Krenz-Niedba<sup>3</sup>a M, Łukasik S, Macudziński J, Chowański S. Morphometry of auditory ossicles in medieval human remains from Central Europe. *Anat Rec (Hoboken)*. 2022;305(8):1947-1961. doi: 10.1002/ar.24842.
- Kuriakose S, Sagar S. Morphometry and variations of malleus with clinical correlations. *Int J Ana Res*. 2014; 2(1):191-194.
- Kamrava B, Roehm PC. Systematic review of ossicular chain anatomy: strategic planning for development of novel middle ear prostheses. *Otolaryngol Head Neck Surg*. 2017;157(2):190-200. doi: 10.1177/0194599817701717.
- Stoessel A, David R, Gunz P, Schmidt T, Spoor F, Hublin JJ. Morphology and function of Neandertal and modern human ear ossicles. *Proc Natl Acad Sci U S A*. 2016;113(41):11489-11494. doi: 10.1073/pnas.1605881113.
- Saha R, Srimani P, Mazumdar A, Mazumdar S. Morphological variations of middle ear ossicles and its clinical implications. *J Clin Diagn Res*. 2017;11(1): AC01-AC04. doi: 10.7860/JCDR/2017/23906.9147